

Reprinted from

✓ 165
1971

Neuropsychologia, 1971, Vol. 9, pp. 247 to 259. Pergamon Press. Printed in England

HEMISPHERIC DECONNECTION SYNDROME WITH CEREBRAL BIRTH INJURY IN THE DOMINANT ARM AREA*

R. D. NEBES† and R. W. SPERRY

Division of Biology, California Institute of Technology, Pasadena, California, U.S.A.

(Received 25 February 1971)

Abstract—Behavioral testing for interhemispheric integration in a commissurotomy boy



PERGAMON PRESS
OXFORD NEW YORK LONDON PARIS

HEMISPHERIC DECONNECTION SYNDROME WITH CEREBRAL BIRTH INJURY IN THE DOMINANT ARM AREA*

R. D. NEBES† and R. W. SPERRY

Division of Biology, California Institute of Technology, Pasadena, California, U.S.A.

(Received 25 February 1971)

Abstract—Behavioral testing for interhemispheric integration in a commissurotomy boy with asymmetric cortical damage indicates a compensatory strengthening in the ipsilateral somesthetic representation of the left hand in the left hemisphere. Unlike previous commissurotomy patients, this subject could name, describe, and locate objects felt by the left as well as the right hand, and could use the left hand to tactually retrieve items, the pictures or names of which had been presented to the right visual field. Evidence was not found for a similar bilateral tactual representation of the right hand. Limited enhancement of language capacities in the minor hemisphere was also found in the form of left handed transcription of printed words into script, and some ability to write and speak about objects in the left hand.

INTRODUCTION

EXAMINATION of patients that have undergone complete surgical section of the corpus callosum and the anterior and hippocampal commissures for the treatment of intractable epilepsy [1] has led in recent years to the demonstration of a large number of definite functional symptoms in man directly associated with the loss of the neocortical commissures. The collective syndrome of hemispheric deconnection as described to date [2-8] has been based very largely on several select cases with minimal preoperative brain injury. The extent to which this syndrome tends to vary in other patients with different conditions and backgrounds related to training, pre-existent brain damage and other factors has yet to be determined. In view of the inherent plasticity of the human cerebral cortex it would not be surprising to find that the organizational pattern of the cerebral commissures, and the functional deficits produced by their section might vary significantly between individuals, especially in the presence of early and long-standing cerebral damage.

The following report describes some observations on another of these commissurotomy patients, a boy with an epileptogenic focus involving the right arm area of the left hemisphere that had triggered seizures from age five and that went back apparently to a cerebral injury sustained at birth. The right hand, though functional and used for writing, has distinct sensory deficits. The special interest in this case concerns the nature and extent to which compensatory functional reorganization in response to the long-standing cerebral lesion might be reflected in the symptoms produced by commissurotomy. Accordingly the

* Supported by a grant from the National Institute of Mental Health (No. MH-03372), of the U.S. Public Health Service.

† Presently at Duke University Medical Center, Durham, N.C.

present observations are focused on manual functions with particular reference to the lateralization of motor control, cross integration involving the hands and related verbal and volitional functions.

CASE REPORT

A.A. was his mother's first child; labor was induced because of toxemia, and he was delivered by forceps fourteen hours later. At the age of four months he had two convulsions associated with fever, but he was thought to be developing normally until age five and one-half when generalized convulsions recurred. These often started with "spasms" or a "drawing up" of the right arm. The EEG indicated generalized abnormalities, more marked over the left hemisphere. A.A. began to fail in school at the fourth grade. The convulsions continued, and despite medical treatment became progressively worse during the next eight years. A fractured clavicle, and a number of head injuries, were sustained in attacks during this period.

On October 14, 1964, at age 14, A.A. underwent cerebral commissurotomy, performed by Philip Vogel and his staff at the White Memorial Medical Center in Los Angeles. The operation included section of the entire corpus callosum and anterior commissure, with presumed section of the hippocampal commissure. The massa intermedia was not visualized. The operation was difficult and required interruption of two large bridging veins, causing right cerebral swelling. While he has had ever since a mildly spastic left leg with a positive Babinski sign, his left arm showed good recovery to approximately the preoperative level. Since 1966 he has attended a school for the handicapped where he has made a good adjustment. Since the operation, he has had occasional episodes of right arm numbness and incoordination often associated with speech arrest. Preliminary testing two years after surgery showed A.A.'s right hand to be subnormal in several respects; the two point threshold was above that of the left, which was normal, and the subject was at times incorrect in judging the direction the first joint of one of his right fingers was moved by the experimenter. There was no deficit in either hand in discriminating pressure as tested with the von Frey hairs. In simple tactile retrieval tasks where the subject had to blindly retrieve from among many objects an item which he had been told to find, or which he had previously felt, the right hand was usually less successful than the left.

METHODS

The testing procedures were similar in general to those already described for studying integrational deficits in human patients with section of the forebrain commissures [2-4]. Most of the tests were carried out in a standard setup (see Fig. 1) in which the subject was seated at a table in front of a projection screen

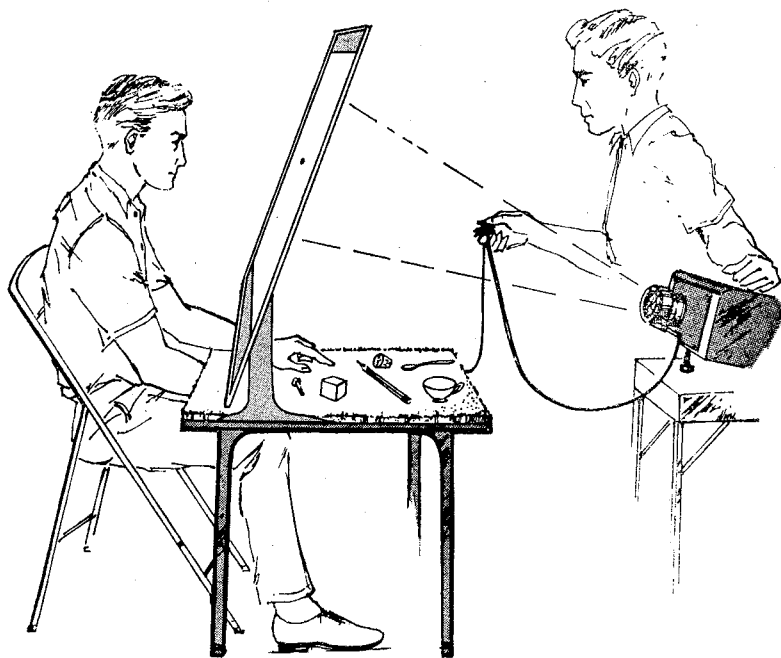


FIG. 1. General testing set up.

of translucent plexiglas that served also to shield from sight the top of the table, the examiner, and the testing equipment. In the centre of the screen at eye level was a black spot upon which the subject kept his gaze centred during the tachistoscopic presentation of visual material. The subject could reach under the screen through a fringe to perform various manual tasks, screened from sight. To minimize auditory cues during tactile testing the stimuli were arranged behind the screen on a thick towel. This testing arrangement allowed for the controlled lateralized testing of different sensory modalities and for separate right-left motor performance of the hands with vision excluded.

Unless otherwise stated the subject was allowed in advance to identify by sight and touch, and to name aloud all of the objects, words or pictures to be used in a given test before the actual trials began. In the case of visual stimuli this involved a free view for several seconds of the projected slide.

It was noted in preliminary testing that when required to identify stimuli in the left sensory field, the subject would often silently mouth over and over the names of the choices. In order to eliminate this possible source of peripheral cross cueing, the patient was forbidden to move his lips or tongue unless giving a definite verbal response. Further procedural details for specific tests are described below in context.

RESULTS

In general the functional deficits observed in this patient were similar to the pattern of impairment seen in the earlier patients mentioned above. Some features of the syndrome, however, demonstrated substantial qualitative as well as quantitative differences [9]. Special emphasis is given below to these latter symptoms that deviated from those previously described in other patients.

Verbal identification of objects in the left hand

With his left hand screened from sight the subject was asked to feel and to verbally describe or name objects placed in the left hand one at a time by the examiner. The simplest task involved stereognostic discriminations based separately on size, weight, or surface texture. For each of these discriminations a set of three cylinders was used. In the set varying in weight the cylinders were wood with lead inserts. All had the same height ($2\frac{1}{2}$ in.), and dia. ($1\frac{1}{4}$ in.) but weighed 100, 150 or 200 g. The size discrimination involved three wood cylinders all 3 in. high but 1 in., $1\frac{1}{2}$ in. or 2 in. in dia. The subject was not allowed to lift these so that weight could not be a cue. For the texture discrimination metal cylinders 2 in. by $\frac{1}{2}$ in. with either a smooth, lightly or heavily knurled surface were used. In this latter test the cylinders were lightly rubbed across the subject's finger tips by the examiner. In all of these tests the subject was shown and allowed to feel the three items of a set before the trials began, and during the test had only to state how the cylinder out of sight in his hand compared to the other two of the given set. In the test for size discrimination, for example, the subject had only to report largest, smallest or medium. The subject's verbal reports for all three types of tactual discrimination made out of sight by the left hand were correct well above the chance level (see Table 1). When the testing was extended to verbal identification of simple shapes in the left hand (a round versus a square wooden rod, both $3\frac{1}{2}$ in. long and $\frac{3}{4}$ in. in diameter) his verbal replies were correct 22 of 24 times ($p < 0.001$).

He was also able under the same conditions as above to give good verbal descriptions of common household objects, such as a spoon, pencil or cup, placed in the left hand. He could describe these objects which he had not seen or named in advance, in terms of their size, texture, material, etc. For example, he characterized a quarter as being "round, thin and made of metal." An oval bar of soap he called "smooth, hard and rounded." A cotton glove was reported as "soft and made of cloth."

In this test where the objects were totally unspecified in advance he occasionally was able to give the exact name of very simple items as, for example, a wooden equilateral triangle. His left hand performance on these tasks was below that for his own right hand

Table 1. Verbalization of stimuli in the left hand

Three cylinders of different texture	16/27	$p < 0.005$
Three cylinders of different weight	24/30	$p < 0.001$
Three cylinders of different diameter	13/13	$p < 0.001$
Two common objects	62/84	$p < 0.001$
Three common objects	103/129	$p < 0.0001$
Three plastic numbers	12/14	$p < 0.01$
Four common objects	59/74	$p < 0.0001$
Four wooden shapes	13/21	$p < 0.001$
Nine common objects	12/56	$p > 0.05$
Touch on one of the five fingers	30/70	$p < 0.001$

or for normal subjects, but was well above that for the subordinate hand in other commissurotomy patients.

When A.A. was allowed before the test to freely examine and name an array of from 2 to 6 test objects, he was then able to report these objects by name when they were presented in random order to his left hand for identification through stereognosis (see Table 1). For example, with random presentations to the left hand of six plastic letters (C, H, M, P, S, T) 5 cm high, he named the correct letter aloud 8 of 16 times ($p < 0.002$). When he did not know in advance what items were to be included in the array of test objects, or if the number of choices exceeded ten, he was usually not able to identify the objects specifically by name.

The level of A.A.'s performance varied somewhat from session to session but generally tended to improve with testing experience. His scores with the right hand in the foregoing tests, as a rule, were somewhat above those for the left hand, despite the right hand's sensory impairment.

Written identification of objects in the left hand

With testing conditions similar to the preceding, the subject was asked to write out with his right hand the name of the test object presented to the left hand instead of speaking it aloud. Both the paper and the right hand were out of sight behind the screen. The written scores obtained under these conditions were quite similar to those for verbal reports of objects in the left hand. In detecting whether the rough or smooth metal cylinder had been lightly drawn across his left fingers his written answers were correct 15 of 15 times ($p < 0.02$). When four wooden shapes (square, triangle, cross and circle, all with a diameter or side of 2 in., and a thickness of $\frac{1}{2}$ in.) were individually presented to the left hand in random order, he wrote the correct name 9 of 18 times ($p < 0.02$). The names of five common household objects (fork, pen, cup, comb, key) randomly presented to the left hand were correctly written with his right hand 14 of 20 times ($p < 0.0001$). When the left instead of the right hand was used to write the answers in the preceding test he was correct 8 of 11 times ($p < 0.001$). Six of the nine errors made by the two hands combined in this last test involved one object (the fork), all presentations of which were incorrectly identified.

At the end of the session it was discovered that the subject had forgotten that this particular object had been included among the five choices. The subject in these tests in which written answers were used to identify objects in the left hand was, as on those involving verbal reports, markedly superior to previous commissurotomy cases.

In related tests the objects to be identified were presented visually by tachistoscopic flash to one or the other visual field and the subject was instructed to write out blindly with the right hand the name of the seen object. Under these conditions he was able to write the correct name for only those pictures presented in the right half field of vision. His inability to name in writing stimuli presented in the left half visual field was quite comparable to other commissurotomy patients. In brief, A.A. was often able to write the names of test objects when they were presented tactually to the left hand but not when the same objects were presented visually as pictures to the left half visual field.

Localization of touch on the left hand

The subject extended his hands palm upwards with fingers spread, underneath and behind the testing screen where, out of the subject's sight, the hands were stimulated by the examiner with light pressure from a blunt plastic stylus. He could always report verbally the onset of contact with either hand. The pressure thresholds for the right and left hands were not noticeably different in this respect. When asked to report which of eight spots on his left arm and hand (lower arm, wrist, palm and the ends of the five fingers) had been lightly touched, his score was well above chance (21/80 $p < 0.001$). The same was true when he had only to report which one of the five fingers of his left hand had been touched (30/70 $p < 0.01$). The right hand scores on this latter test were somewhat better but also subnormal (12/20 $p < 0.0001$).

With both hands screened from view the subject was instructed to move the finger on his left hand that corresponded to the one touched by the examiner on his right hand, and vice versa. It was found that he could perform this task from the left to the right hand but not in the reverse direction, from the right to the left. When a finger on the left hand was touched he correctly moved the corresponding finger on his right hand 21 of 49 times ($p < 0.001$). The scores obtained for the opposite direction were at the chance level (10/44, $p = 0.38$). A good deal of perseveration was evident in this latter situation.

The observed ability of the subject to verbally localize points touched on the distal part of his left hand and arm, though well below that of normals, was much better than has been demonstrated in any of the previously reported commissurotomy cases. Also, previous patients have not been able to respond in either direction with the corresponding finger after tactile stimulation of a finger on the opposite hand.

Tactual cross retrieval

In this test an object was placed in one of the subject's hands for examination by touch, after which it was removed and scrambled among an array of other test objects for retrieval by the opposite hand. This entire process was carried out with both hands screened from view behind an upright screen, and with controls for auditory cues. Significant scores were obtained for cross retrieval in both directions for the three sets of cylinders described above. When the right hand was required to retrieve from among the three cylinders of a set the one which the left hand had felt, the score was 10 of 15 ($p < 0.01$) for size discrimination, 14 of 22 ($p < 0.01$) for weight discrimination, and 11 of 15 ($p = 0.002$) for roughness discrimination. With left-handed retrieval of cylinders felt by the right hand he was correct 10 of 15 times for size ($p < 0.01$), 14 of 24 times for weight ($p < 0.02$), and 13 of 18 times for texture ($p < 0.001$).

When common household objects were used, or items like wooden blocks or plastic letters that varied only in shape, A.A. was not able to cross retrieve with any significant success. Even with three objects (pen, key, cork) varying markedly in their tactile qualities no reproducible positive results were obtained.

Visuo-tactile matching

Here the patient was instructed to retrieve by touch from among an array of objects behind the screen the item that matched a picture flashed tachistoscopically to one or the other visual fields. In early tests, pictures of fifteen common household objects (key, spoon, pencil, cork, coin, etc.) were used, with the objects themselves set in scrambled order behind the screen for tactual inspection. Under these conditions A.A., like previous patients, had no trouble finding the correct object with the hand ipsilateral to the half field receiving the visual stimulus. The sensory deficit of the right hand did not appreciably affect his performance when the picture was in the right field. When, however, required to use the hand contralateral to the visual field in which the picture was presented, A.A. performed successfully in one direction but not in the other. With his left hand A.A. was able to find objects pictured in the right visual field (see Table 2). Similar results were obtained when the printed names of the objects rather than their pictures were flashed to the left or right visual field. Here as before, the hand ipsilateral to the field of presentation was readily used to find the named objects. Again in the cross retrieval situation the left hand could be used to find objects the name of which was shown only in the right half visual field (see Table 2).

In further testing, the subject was requested after each retrieval to name the picture which he had seen. Only for those trials in which the picture was flashed to the right visual field could he say the name. In spite of this inability to name objects in the left field he was, as in the previous tests, able to find the correct objects with his left hand. Upon flashing the cue to the right half field he could find the object with the left as well as the right hand, and could name the picture (see Table 2). The results of the foregoing naming and retrieval tasks were similar whether the items used were fifteen common objects, six wooden shapes, or six plastic letters. In these tests A.A. alone of the commissurotomy cases reported to date has shown an ability to do crossed intermodal matching, using his left hand to find objects, the identity of which had been revealed by visual cues in the right half field only.

Visuo-visual matching

In tests for the crossing of visual information between the hemispheres one of six geometric shapes was tachistoscopically presented in one or the other visual field, followed three seconds later by the flash presentation in the same or opposite field of two of these shapes vertically arranged, one above and one below the level of fixation. One of the two stimuli seen in the second presentation was the same as in the first and the subject was asked to point to the place on the screen where the matching form had appeared and then to name it. Only when both presentations fell in the same visual half field was he able to point out the correct shape above the chance level. He could correctly name the shape only in those trials in which the first presentation was in the right visual field (see Table 3). A.A.'s performance in this task is what would be expected from the results of tachistoscopic visual testing in the other commissurotomy cases.

Copying of geometric forms

This test required blind copying of geometric forms by the hands ipsilateral and contralateral to the visual field in which the forms were tachistoscopically presented. All

Table 2. Visuo-tactile matching

	LVF—Left Hand		RVF—Right Hand		RVF—Right Hand		RVF—Left Hand	
	Picked	Named	Picked	Named	Picked	Named	Picked	Named
Pictures of 15 objects	8/15 $p < 0.0001$	—	4/24 N.S.	—	17/21 $p < 0.0001$	—	8/15 $p < 0.0001$	—
Printed names of 15 objects	6/15 $p < 0.002$	—	4/23 N.S.	—	13/22 $p < 0.0001$	—	13/23 $p < 0.0001$	—
Pictures of 15 objects	13/15 $p < 0.0001$	2/15 N.S.	2/16 N.S.	2/16 N.S.	12/14 $p < 0.0001$	12/14 $p < 0.0001$	14/15 $p < 0.0001$	14/15
Pictures of 6 wooden shapes	18/19 $p < 0.001$	4/19 N.S.	5/21 N.S.	5/21 N.S.	16/21 $p < 0.0001$	21/21 $p < 0.0001$	20/30 $p < 0.001$	29/30 $p < 0.001$
Pictures of 6 plastic letters	6/7 $p < 0.001$	3/7 N.S.	1/7 N.S.	1/7 N.S.	8/11 $p < 0.001$	10/11 $p < 0.0001$	5/10 $p < 0.015$	9/10 $p < 0.0001$

LVF=Left Visual Field

RVF=Right Visual Field

N.S.=Nonsignificant.

Table 3. Visuo-visual matching of six geometric shapes

	R.V.F. then R.V.F.	L.V.F. then L.V.F.	R.V.F. then L.V.F.	L.V.F. then R.V.F.
Picked (Chance=1/2)	15/20 $p < 0.02$	18/20 $p < 0.001$	4/20 N.S.	5/20 N.S.
Named (Chance=1/6)	3/20 N.S.	19/20 $p < 0.001$	5/20 N.S.	20/20 $p < 0.0001$

combinations of visual half field and hand were found to be proficient. The use of the hand contralateral to the field receiving the visual cues did not cause any noticeable deficit in the quality of the reproduction. The right hemisphere-right hand combination in particular was found to be more accurate and stable and generally more proficient in its performance than was the case in the earlier commissurotomy patients.

Written identification of stimuli in one half visual field

In these tests the subject was asked to write blindly the name of a stimulus flashed to one half visual field. Before each session began all stimuli to be used, words or object pictures, were presented to the subject in free view and he was asked to say their names aloud. The same stimuli were then presented tachistoscopically with the order of presentation and the alternation between visual fields randomized. After a stimulus had been flashed, the subject wrote his answer with one or the other hand on pad out of sight and then named aloud the word he had written. In all cases he spontaneously wrote in script.

In the first task the visual stimuli were 10-15 short common printed nouns (cup, pen, key, etc.). When the words fell in the right half field the results were similar to previous cases and to normals. He was able to write the correct name with either the right (18/22) ($p < 0.01$) or left hand (16/24) ($p < 0.01$) and could always name what he had written. When the stimuli fell into the left visual field his performance with his right hand reflected the deficits seen in the previous commissurotomy cases. The words written were never correct (0/24) and he always named what he had written, thus demonstrating major hemisphere guessing. In using the left, subordinate hand to write the answers his performance was quite different from that of previous subjects. Of the 39 presentations of printed nouns to the left field in which the left hand was used to write the answer he wrote in script the correct word 12 times. On 10 of these occasions he then either could not name or misnamed the word he had just written, indicating minor hemisphere performance (see Fig. 2). The words he correctly wrote but misnamed were "cup," "comb," "dog," "key," "eye" (twice), "book" (twice), and "cat" (twice) (see Fig. 3a). On the 27 times he wrote with his left hand an incorrect word to a left field presentation he always could say what he had written, suggesting that in these exceptions the major hemisphere was doing the writing.

When printed verbs instead of nouns were tried, it was again only the left visual field-left hand combination that gave results which differed from the typical commissurotomy syndrome. Of the 12 presentations to the left field the left hand wrote two possibly correct answers. In the first case when the word presented was "lie" he wrote "li," stopped, added "n" and said "run." In the second case (see Fig. 3b) the word was

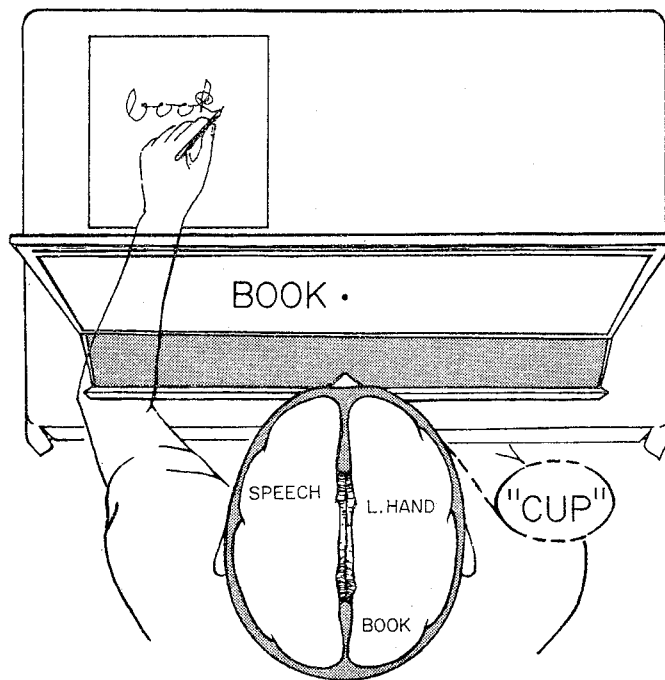


FIG. 2. An example of left hand writing to a left field presentation, followed by incorrect verbalization. The written word shown is an actual half size reproduction of the subject's answer.

"sit"; he wrote "si," stopped, added "mp" and said "jump." Both "jump" and "run" were words known by the subject to be on the test. In other trials the major hemisphere apparently dominated the left hand response throughout, and only incorrect answers, which he could later verbalize, were obtained.

In a third task A.A. was required to write the names of 15 common objects, the pictures of which were flashed to one or the other visual field. Most of the pictures were of objects, the printed names of which had been the stimuli in the first test. Again before the test began he was shown the stimuli with free vision and was asked to name them. When the pictures were in the right field, as expected he was very successful with either the right (16/16) or the left (38/43) hands. When the pictures were presented in the left half field, the right hand was correct only 2 of 15 times. On both of these occasions he correctly named what he had written. Using the left hand, of the 54 tachistoscopic flashings of pictures to the left visual field the subject wrote the correct word six times, but on only two of these occasions did he then fail to name what he had written. In both of these exceptional successes the picture was of a Siamese cat greatly resembling the family pet. On the first occasion when asked what he had written he tried to peer over the screen and when prevented admitted that he did not know. In the second case he wrote "cat," stopped, said "No, that's wrong," added two loops (Fig. 3c) and then said "bottle." On all other presentations to the left field he wrote an incorrect word and then named the word he had written. He wrote "cat" only once to an inappropriate picture.

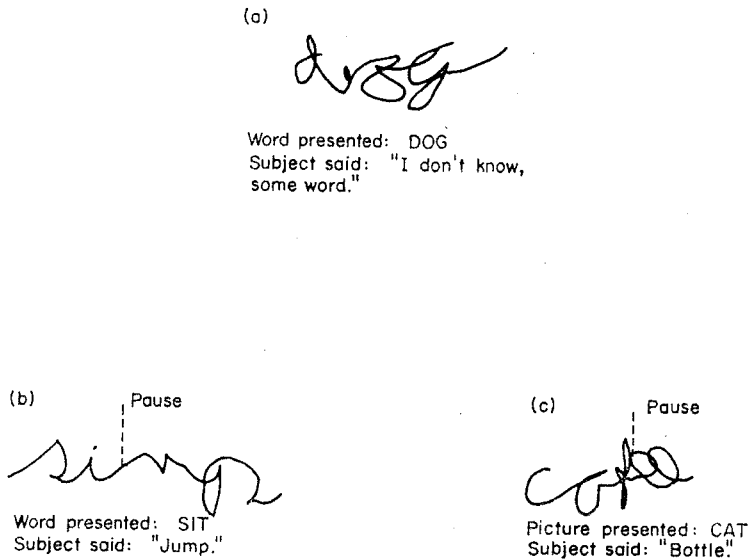


FIG. 3. Illustrations of writing by the left hand after presentation of words or pictures in the left visual field.

DISCUSSION

Compared with previous commissurotomy cases of the Voge series the present subject showed exceptional preservation of cross-integration involving manual functions. This was evident in his ability to verbally describe stimuli in the left hand, including the size, weight, texture, and upon occasion, even the shape and identity of test items. Superior cross-integration was also found in tests where the left hand was used to find objects exposed in the right half field of vision. All these performances appear to involve an enhancement of this patient's capacity to use left hand stereognosis in conjunction with processes controlled from the major hemisphere. In contrast, tasks not involving manual functions such as cross-matching between the right and left visual fields or naming of left field visual stimuli, were subject to the typical right-left disruption of cross-integration. The selective superiority in cross-integration takes on added significance in view of the generalized slowing of physical and mental activity that otherwise prevailed in this individual, presumably caused by diffuse brain damage.

While the combined results suggest that the left hemisphere has access to tactual information from the left hand, there is no evidence that the minor hemisphere has a similarly enhanced accessibility to touch from the right hand. Successful cross-localization for cutaneous stimulation of the fingers occurred in one direction only (from the left to the right hand), and the same was true in visual-tactile matching. Taken together the observations point to the conclusion that the stereognostic representation of the left hand is exceptionally well developed in the left hemisphere of this patient. Presumably this enhancement of function in the ipsilateral system for the left hand was developed to compensate for the cerebral birth injuries that affected right hand function.

The reason for the failure to cross-retrieve shapes is not clear. It cannot be attributed entirely to the right hand sensory deficit as oftentimes the subject was able to correctly name an item which he had failed to find with his left hand. Why tactual retrieval with

the left hand should fail under these conditions and succeed with visual input to the major hemisphere remains to be explained. Visuo-tactile matching of nonsense shapes by children, however, has been found by RUDEL and TEUBER [10] to be significantly easier than tactual-tactual matching. Accordingly A.A.'s failure to cross-retrieve forms may be attributable to the greater difficulty of this type of matching for a person of such lowered capacities.

The number of stimuli the subject's left hemisphere could successfully discriminate through the left hand varied from six, in verbal identification tests, to over fifteen in visual-tactile matching. This probably reflects the differing requirements of these tasks on the ipsilateral system. In order to name an object in the left hand, the major hemisphere must review its past experiences through the left hand with all the possible choices and compare these with the present input. The greater the number of items, the more complex the comparison, and the more likely the subject will forget some of the choices.

The simplest explanation for the discrepancy between the present and previous patients would seem to be provided in terms of a compensatory increase in the functional proficiency of the ipsilateral tactual pathways for the left hand. The presence of such pathways providing an ipsilateral cortical representation of the limbs, especially in Somatosensory II, has been well documented [11-14]. SEMMES [15] has recently shown in the monkey that unilateral somatosensory lesions significantly disturb performance on a tactual discrimination by the ipsilateral hand. The time of A.A.'s original injury would also be an important factor since the age at which cortical damage occurs has been shown to greatly affect the upper limit of compensation. Patients with hemispherectomy for infantile hemiplegia demonstrate ipsilateral somesthesia far above the level found after the removal of a hemisphere damaged in adulthood [16, 17]. The basis for the demonstrated enhancement of the left rather than the right ipsilateral tactual system may be found in findings by SEMMES [18] that the left hand, more than the right, is likely to have bilateral functional representation in the cortex. Since compensation is probably achieved through the enhanced use of pre-existing pathways this would predispose readjustments in favor of a left-sided system.

In addition to his superior ipsilateral manual abilities this subject also demonstrated an enhanced capacity for minor hemisphere language not previously observed in these commissurotomy patients. With his left hand, he could transcribe into script a printed word presented to only the minor hemisphere. Inability to then vocally name the word written with the left hand makes it probable that the major hemisphere did not participate in this writing. The frequent writing of incorrect words which could then be verbalized demonstrated further the tendency of the leading hemisphere to override the minor hemisphere in control of left-hand writing. Shift of motor control from the minor to the major hemisphere was observed to occur several times in the midst of a word after the left hand had begun to write one or two letters of the correct answer. The writing by the minor hemisphere was not mere copying of a visual form but required comprehension of the test symbols as the stimuli were printed while the subject's answers were always in cursive script. This capacity to deal with symbols seemed to be limited, however, to comprehension and copying of simple familiar words and did not extend as a rule to writing the names of pictured objects.

Recently, other experiments with A.A. [19] have suggested that, when the restrictions on preparatory mouth movements imposed in the current study are lifted, his minor hemisphere may be capable of initiating some vocalization. This finding does not, however,

invalidate the present conclusions as to the existence in this patient of an ipsilateral tactual system, since these are based largely on the results of nonverbal tasks, such as visual-tactile matching, but rather it demonstrates the scope of the compensatory shift in language laterality which has occurred in this patient.

In general the symptom deviations exhibited by this patient may be regarded as an example of the wide spectrum of behavioral variations that can be expected to result from early damage to still plastic neocortical systems. An extreme of such compensatory reorganization is illustrated by an asymptomatic patient with total agenesis of the corpus callosum [20]. Individual variations in genetic as well as developmental and experimental factors, such as those underlying handedness and hemispheric specialization help to make for a considerable diversity in the pattern of commissurotomy symptoms displayed by specific individuals.

Acknowledgments—The authors thank Drs. PHILLIP VOGEL and JOSEPH BOGEN for permission to examine their patients, for providing the summary of the medical case history, and for many helpful suggestions.

REFERENCES

1. BOGEN, J. E. and VOGEL, P. J. Cerebral commissurotomy: a case report. *Bll. Los. Ang. neurol. Soc* **27**, 169–172, 1962.
2. GAZZANIGA, M. S., BOGEN, J. E. and SPERRY, R. W. Laterality effects in somesthesia following cerebral commissurotomy in man. *Neuropsychologia* **1**, 209–215, 1963.
3. GAZZANIGA, M. S., BOGEN, J. E. and SPERRY, R. W. Observations on visual perception after disconnection of the cerebral hemispheres in man. *Brain* **88**, 221–236, 1965.
4. GAZZANIGA, M. S., BOGEN, J. E. and SPERRY, R. W. Dyspraxia following division of the cerebral commissures. *Arch. Neurol.* **16**, 606–612, 1967.
5. GAZZANIGA, M. S. and SPERRY, R. W. Language after section of the cerebral commissures. *Brain* **90**, 131–148, 1967.
6. GORDON, H. W. and SPERRY, R. W. Lateralization of olfactory perception in the surgically separated hemispheres of man. *Neuropsychologia* **7**, 111–120, 1969.
7. MILNER, B., TAYLOR, L. and SPERRY, R. W. Lateralized suppression of dichotically presented digits after commissural section in man. *Science* **161**, 184–186, 1968.
8. SPERRY, R. W., GAZZANIGA, M. S. and BOGEN, J. E. In *Handbook of Clinical Neurology*, P. J. VINKEN and G. W. BRUYN (Editors), Vol. 4, pp. 273–290. North-Holland, Amsterdam, 1969.
9. NEBES, R., BOGEN, J. E. and SPERRY, R. W. Variations of the human cerebral commissurotomy syndrome with birth injury in the dominant arm area. *Anat. Rec.* **163**, 235, 1969.
10. RUDEL, R. G. and TEUBER, H. L. Cross modal transfer of shape discrimination by children. *Neuropsychologia* **2**, 1–8, 1964.
11. WOOLSEY, C. N. and FARMAN, D. Contralateral, ipsilateral, and bilateral representation of cutaneous receptors on somatic areas I and II of the cerebral cortex of pig, sheep and other mammals. *Surgery* **19**, 684–702, 1946.
12. ADEY, W. R. and DERR, D. I. B. The cerebral representation of deep somatic sensibility in the marsupial phalanger and rabbit: an evoked potential and histological study. *J. comp. Neurol.* **100**, 597–625, 1954.
13. NAKAHAMA, H. Contralateral and ipsilateral cortical responses from somatic afferent nerves. *J. Neurophysiol.* **21**, 611–632, 1958.
14. WHITSEL, B. L., PETRUCCELLI, L. M. and WERNER, G. Symmetry and connectivity in the map of the body surface in a somatosensory area II of primates. *J. Neurophysiol.* **28**, 473–485, 1965.
15. SEMMES, J. and MISHKIN, M. Somatosensory loss in monkeys after ipsilateral cortical ablation. *J. Neurophysiol.* **28**, 473–485, 19.
16. FRENCH, L. A. and JOHNSON, D. R. Examination of the sensory systems in patients after hemispherectomy. *Neurology* **5**, 390–393, 1955.
17. GARDNER, W. J., KARNOSH, L. J., MCCLURE, C. C. and GARDNER, A. K. Residual function following hemispherectomy for tumors and for infantile hemiplegia. *Brain* **78**, 487–502, 1955.
18. SEMMES, J., WEINSTEIN, S., GHENT, L. and TEUBER, H. L. *Somatosensory Changes After Penetrating Brain Wounds in Man*. Harvard University Press, Cambridge, Mass., 1960.
19. TREVARTHEN, C. T. Personal communication.
20. SPERRY, R. W. Plasticity of neural maturation. In *The Emergence of Order in Developg Systems*, (27th Symp. Soc. Devel. Biol.), M. LOCKE (Editor), pp. 306–327. Academic Press, New York, 1968.

Résumé—Les résultats d'un examen comportemental sur l'intégration interhémisphérique d'un jeune garçon ayant subi une commissurotomie et présentant une atteinte corticale asymétrique montrent un renforcement compensatoire de la représentation somesthésique ipsilatérale de la main gauche. A la différence des autres sujets ayant subi une commissurotomie, ce malade pouvait nommer, décrire et localiser les objets palpés par la main gauche aussi bien que ceux palpés par la main droite; ils pouvait utiliser la main gauche pour retrouver tactilement les items dont les noms ou les images avaient été présentés à son champ visuel droit.

On ne constata pas une représentation tactile bilatérale similaire de la main droite. Une augmentation limitée des capacités de langage sur l'hémisphère mineur fut aussi constatée; le malade pouvait avec la main gauche transcrire en manuscrit des mots imprimés et nommer ou décrire oralement ou par écrit des objets placés dans la main gauche.

Zusammenfassung—Verhaltensuntersuchungen bezüglich einer interhemisphärischen Integration bei einem Jungen mit durchschnittener Kommissur und einem asymmetrischen kortikalen Schaden zeigten hinsichtlich der linken Hemisphäre eine stärkere Kompensation in der ipsilateralen Empfindung für die linke Hand. Im Gegensatz zu Patienten mit vorausgegangener Commissurotomie konnte dieser Patient Objekte, die er mit der linken oder rechten Hand tastete, benennen, beschreiben und lokalisieren. Er war auch imstande, mit der linken Hand das zu ertasten, was er bildhaft oder als Namen in der rechten optischen Gesichtsfeldhälfte präsentiert bekam. Eine ähnliche bilaterale taktile Repräsentation wurde für die rechte Hand nicht gefunden. Für die linke Hemisphäre wurde also eine begrenzte Verbesserung der Sprachleistungen in der Weise gefunden, daß linkshändige Übertragung gedruckter Wörter in einen Schreibtext vorgenommen werden und über Objekte, die man der linken Hand gab, geschrieben und gesprochen werden konnte.